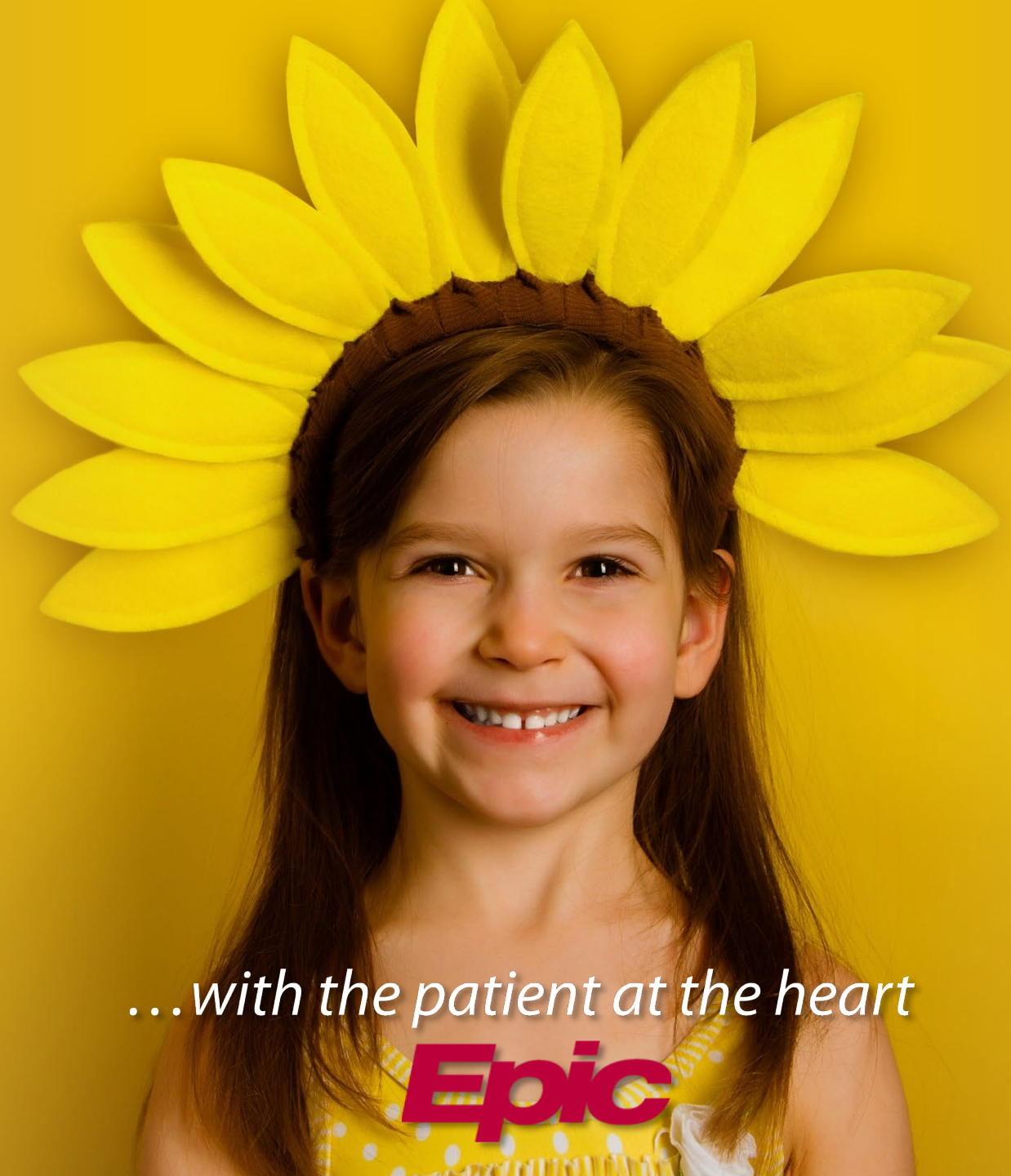

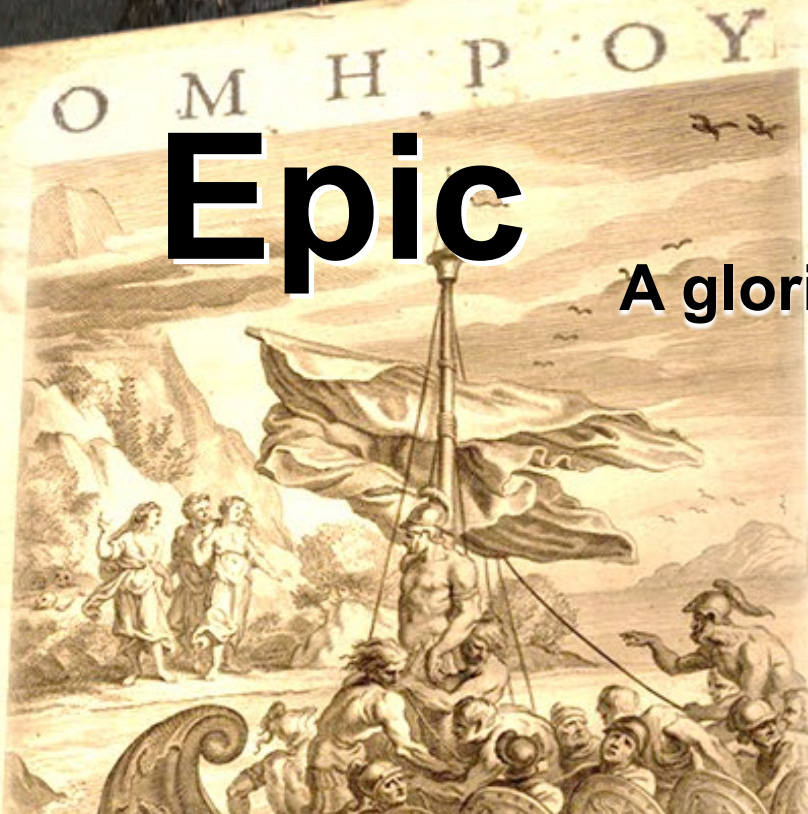


...with the patient at the heart

Epic

Epic

A glorious account of a nation's events



Ο ΜΗΡΟΥ

ΟΔΥΣΣΕΙΑ.

Η ΟΜΕΡΕΙ

ΟΔΥΣΣΕΙΑ.

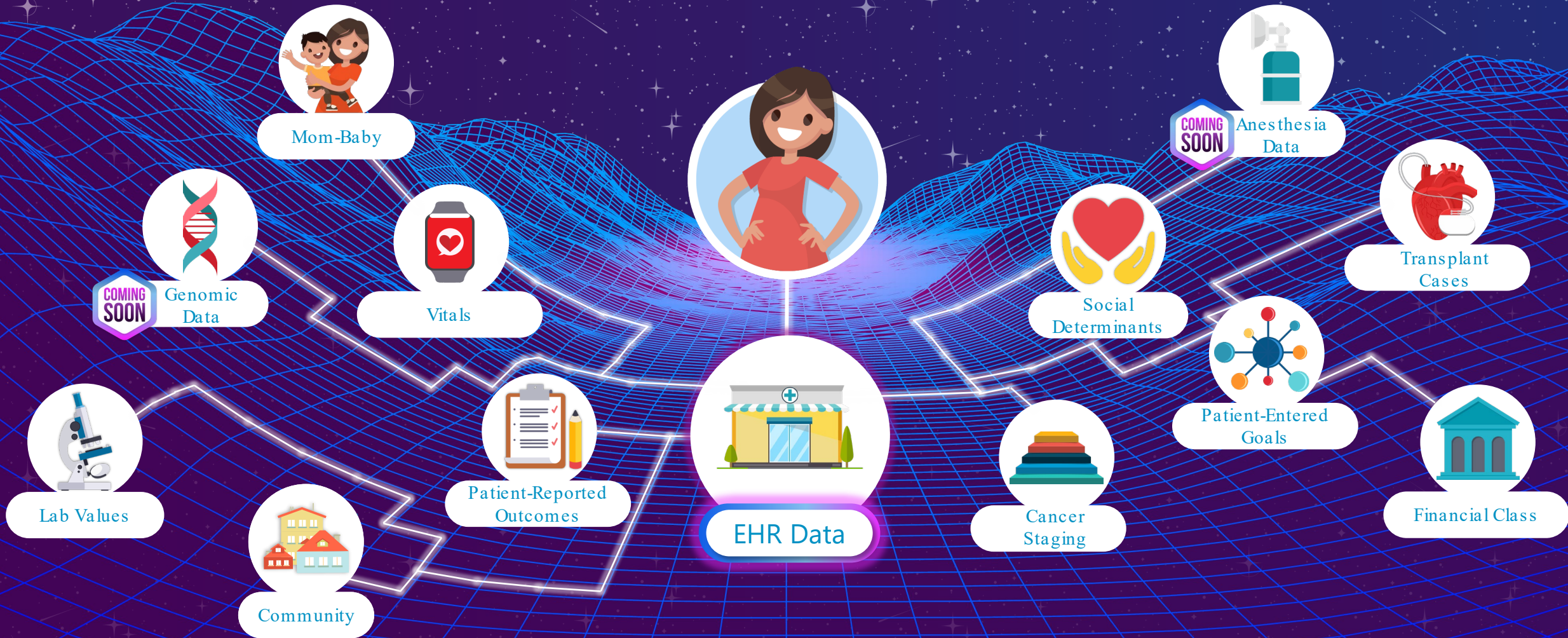
DE REBUS AB VLVSSE GESTIS.

Eiusdem Batrachomyomachia
& Hymni.

Latina versione ad verbum è regione appositæ.



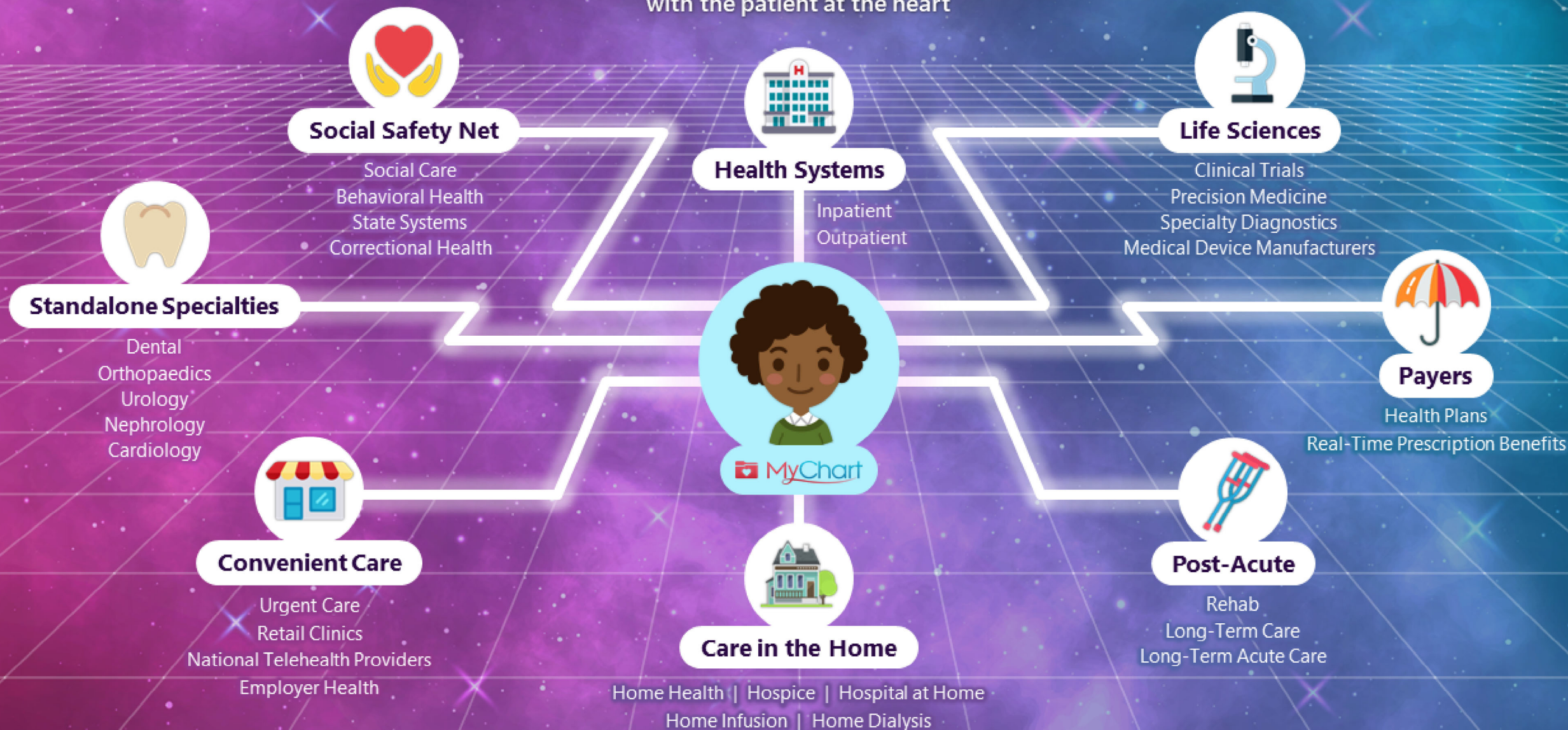Many data sources, one integrated patient record



HEALTH GRID

bringing data together
with the patient at the heart

Cosmos




Workforce Supporting Cancer Surveillance



- **Patients**
- **Clinicians and Researchers**
- **Health Care Organizations**
- **AI-Empowered Care Teams**

What you can do now!



Julie Cobb

Female, 50 y.o., 3/31/1973
Pronouns: she/her/hers
MRN: 900203
☐ Scheduled
Code: Prior (has ACP docs)

COVID-19 Vaccine: Unknown
Isolation: None
Eligible for lung cancer screening

PCP: Me
Primary Cvg: Epic Us Healthcare/...

Allergies: Ace Inhibitors

11:00 AM OFFICE VISIT
Wt: 79.4 kg >7 days

SINCE YOUR LAST VISIT
No visits
Lab (1)

CARE GAPS

- Lung Cancer Screening Share...
- SARS-CoV-2 (COVID-19) Vac...
- Pap Smear
- Mammogram
- 3 more care gaps

PROBLEM LIST
Essential Hypertension
Hypercholesterolemia
Hypothyroidism

Current Visit

SnapShot

Chart Review

Synopsis

Lifet

Current Visit

Best Practice Med Management SmartSets

Best Practice Advisories

No advisories to address.

Medication Management

+ Comments

+ Patient-Reported

Name	dh
atenolol (TENORMIN) 50 MG tablet	
ketoprofen (ORUDIS) 50 MG tablet	
levothyroxine (SYNTHROID) 50 MCg tablet	
simvastatin (ZOCOR) 20 MG tablet (EpiPen)	

Apothecary 608-555-1313

Mark as Reviewed Last Reviewed by Drew Walker, 10/20/2023 10:10 AM

Care Gaps

Close care gaps

Overdue

Never done	Lung Cancer Screening Shared Decision Making (Every 5 Years)
Never done	SARS-CoV-2 (COVID-19) Vaccine (1)
FEB 5 2021	Pap Smear (Every 3 Years) Last completed: Feb 5, 2018
NOV 3 2021	Mammogram (Every 2 Years) Last completed: Nov 3, 2019
JUL 30 2023	TSH Test Yearly (Yearly) Last completed: Jul 30, 2022
AUG 1 2023	Influenza Immunization (Yearly, August to March) Last completed: Sep 6, 2012

12:27

Mychartbedside.com/patientview

MyChart bedside by Epic

Joey's Hospital Stay

Epic Medical Center

Admitted on Aug 21, 2023

Est. Discharge -

Current status

Transplant surgery prep

Coming up next

Transplant surgery

Around 1:00 PM

Joey's surgery will roughly take 3 hours. After that, he will be taken to PACU for recovery.

Learn more about Joey's surgery

View past events

Updates about Joey

Friends and family can send updates about Joey's hospital stay.

Martin LaDuc

FIGURE 1

Colorectal Cancer Screening Rates

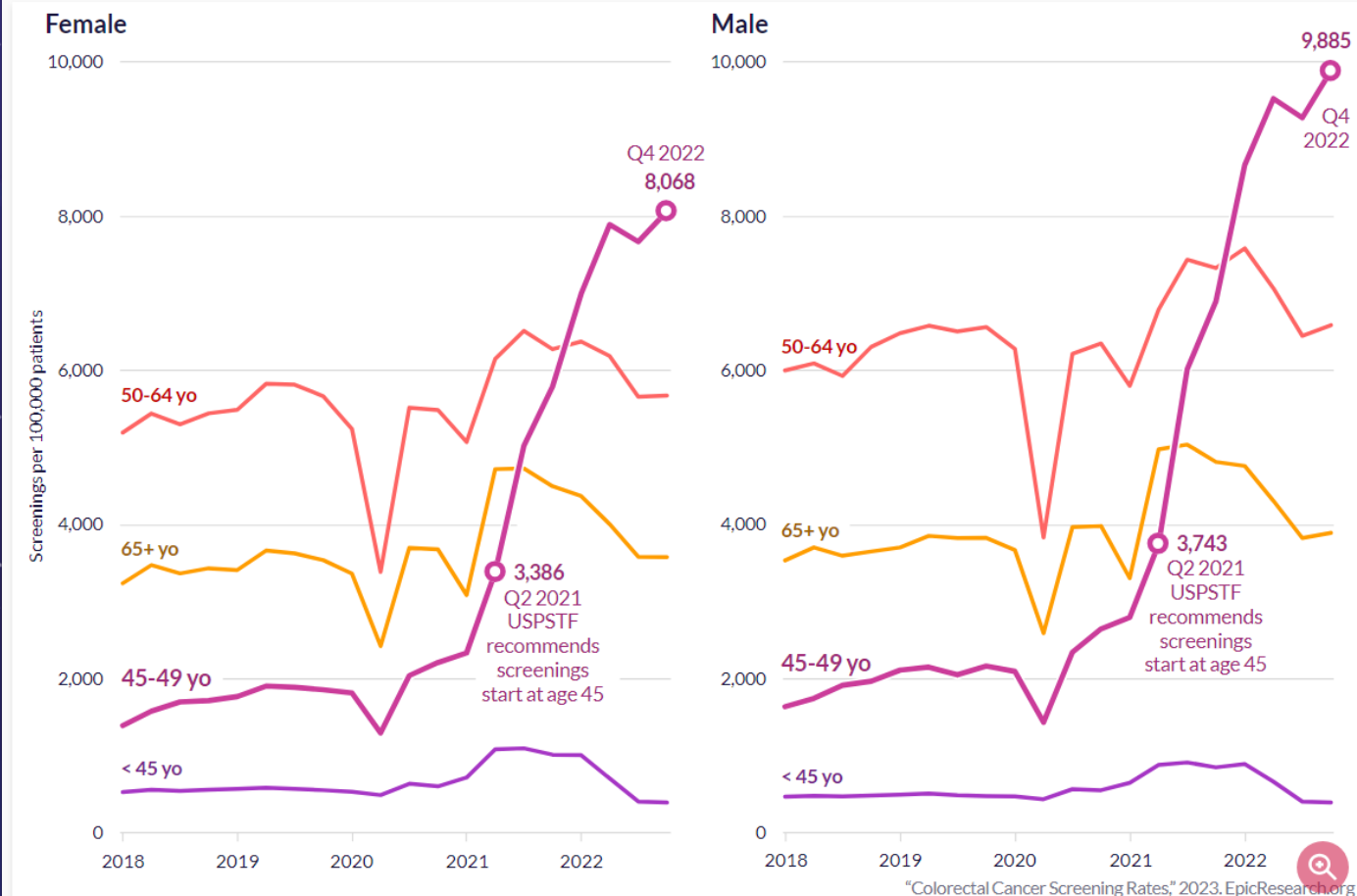


Figure 1. Quarterly rates of colorectal cancer screening per 100,000 patients stratified by sex and age group. Patients under age 45 are not currently included in USPSTF's recommendation for colorectal cancer screenings.

[← Back to Data Tracker](#)

Cancer Incidence Rates

According to the American Cancer Society, cancer [affects one in three Americans](#) in their lifetime. We aimed to trend how cancer screenings and diagnoses have changed over time, and how they were influenced by the pandemic. Our data tracker shows the quarterly rates of overall and advanced cancer diagnoses over the past five years to understand overall trends in cancer, including breakdowns for specific cancer types.

[All](#)[Breast](#)[Cervical](#)[Colorectal](#)[Lung](#)[Prostate](#)

Cancer continues to be [a leading cause of death worldwide](#). Many initiatives have sought to reduce the overall incidence of cancer and especially focus on catching cancer at earlier stages, when it is more treatable and less likely to lead to death. This data tracker focuses on the overall incidence of all types of cancers and the rate of initial diagnosis at advanced stages.

Colorectal cancer is the [second leading cancer-related death](#) in the U.S. In 2021, [colorectal cancer screening guidelines expanded](#) to include younger patients in an effort to increase early identification of potential colorectal cancer. According to the [American Cancer Society](#), colorectal cancer diagnoses have dropped since the 1980s, partially due to increased screenings.

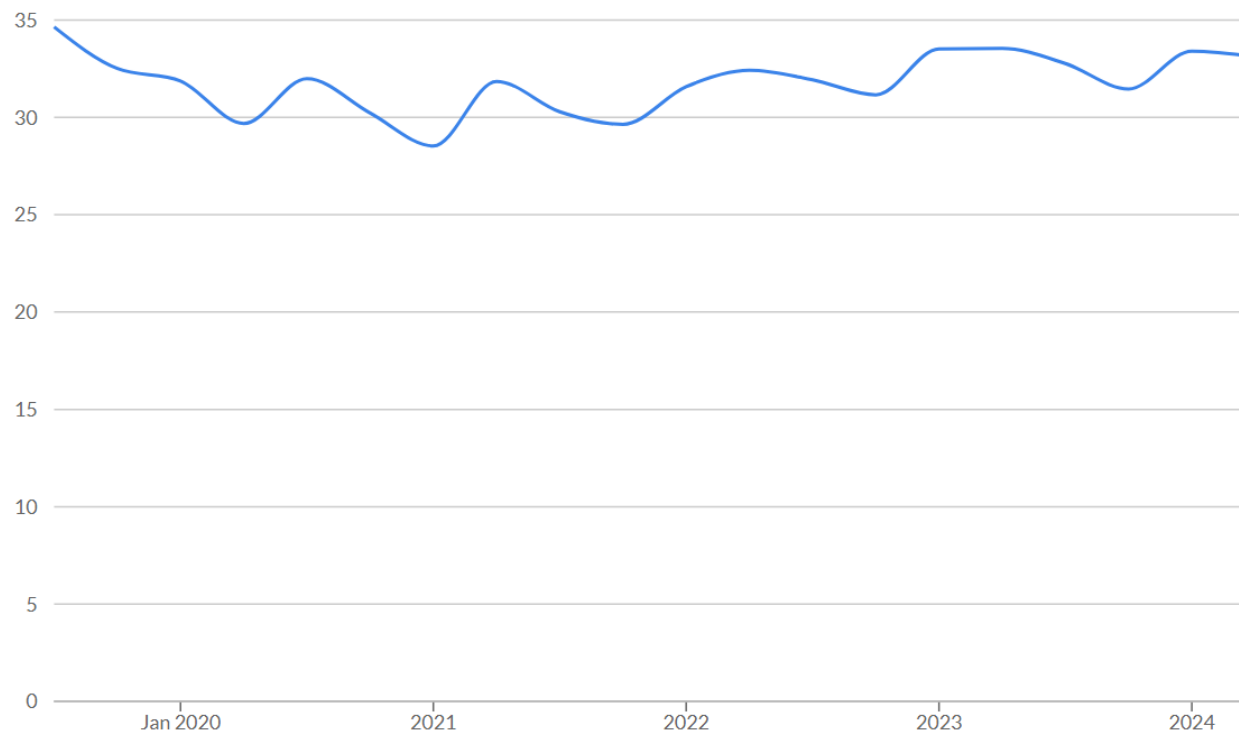
Colorectal Cancer Cases

Q2 2024 (through Invalid Date)

—◆— **33.1**

Colorectal Cancer Cases

Quarterly rates of new cancer diagnoses per 100,000 patients.



The Spectrum of Artificial Intelligence



Rule-Based Logic

Expert-defined and explicitly coded



Predictive Analytics

Statistically-derived to predict a pre-defined event



Generative AI (Large Language Models)

Generally-trained to generate novel content

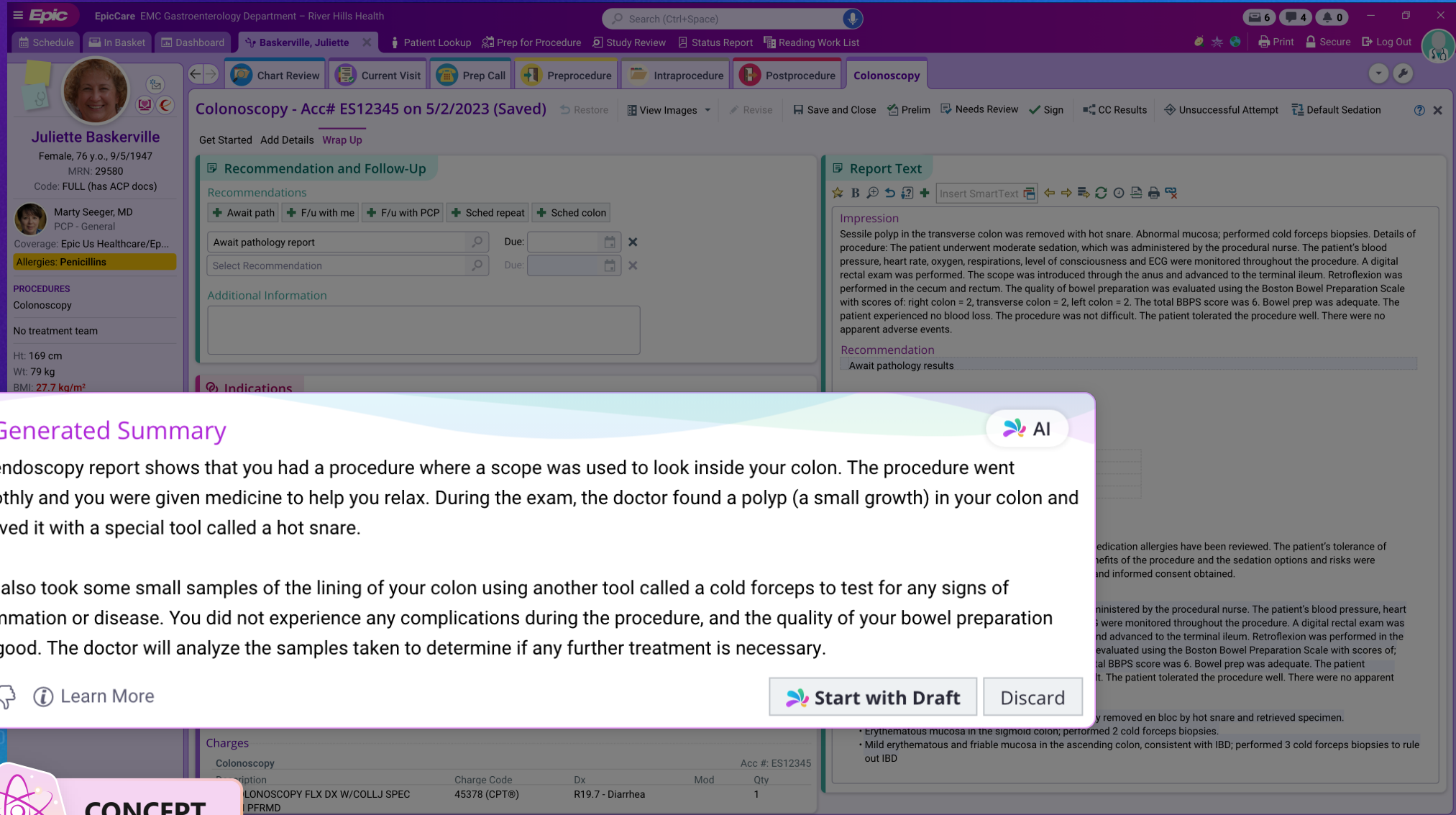
Deterministic

Targeted

Probabilistic

More generalized

Engage Patients *with* Patient-Friendly Reports



Colonoscopy - Acc# ES12345 on 5/2/2023 (Saved)

Recommendation and Follow-Up

Recommendations

- ☐ Await path
- ☐ F/u with me
- ☐ F/u with PCP
- ☐ Sched repeat
- ☐ Sched colon

Additional Information

Report Text

Impression

Sessile polyp in the transverse colon was removed with hot snare. Abnormal mucosa; performed cold forceps biopsies. Details of procedure: The patient underwent moderate sedation, which was administered by the procedural nurse. The patient's blood pressure, heart rate, oxygen, respirations, level of consciousness and ECG were monitored throughout the procedure. A digital rectal exam was performed. The scope was introduced through the anus and advanced to the terminal ileum. Retroflexion was performed in the cecum and rectum. The quality of bowel preparation was evaluated using the Boston Bowel Preparation Scale with scores of: right colon = 2, transverse colon = 2, left colon = 2. The total BBPS score was 6. Bowel prep was adequate. The patient experienced no blood loss. The procedure was not difficult. The patient tolerated the procedure well. There were no apparent adverse events.

Recommendation

- ☐ Await pathology results

Generated Summary

The endoscopy report shows that you had a procedure where a scope was used to look inside your colon. The procedure went smoothly and you were given medicine to help you relax. During the exam, the doctor found a polyp (a small growth) in your colon and removed it with a special tool called a hot snare.

They also took some small samples of the lining of your colon using another tool called a cold forceps to test for any signs of inflammation or disease. You did not experience any complications during the procedure, and the quality of your bowel preparation was good. The doctor will analyze the samples taken to determine if any further treatment is necessary.

Charges

Description	Charge Code	Dx	Mod	Qty
COLONOSCOPY FLX DX W/COLLJ SPEC	45378 (CPT®)	R19.7 - Diarrhea		1



CONCEPT

Extracted Synoptic Results

The screenshot displays the Epic EMR interface. On the left, the 'Outstanding List - EMH Hospital Lab - AP Outstanding List' is visible, showing a table of lab results. The patient's name, 'Beaker, Kasey', and MRN, '203678', are displayed. The 'Tissue Exam' section shows the final diagnosis: 'A. Right Breast Mesectomy' with findings: '1. Residual invasive ductal carcinoma' and '2. Atypical ductal hyperplasia, focal'. A pop-up window titled 'Generated Synoptic Results' is overlaid on the screen, displaying AI-generated synoptic results from the final diagnosis and findings. The pop-up includes a list of findings: 'Excision', 'Residual Invasive Ductal Carcinoma', 'Right Breast Mastectomy', and 'Upper outer quadrant'. Below the list are buttons for 'Accept Results' and 'Reject', and a 'Learn More' link. On the right, the 'Extract Results' section is visible, showing a list of extracted results for the specimen, including 'Excision (less than total mastectomy)' and 'Specimen Laterality: Right'. The 'TUMOR' section shows the tumor site as 'Upper outer quadrant'.

ID	Name	Test	R	L	*Responsible	Status
LP15-0002	Infection Con...	Pap test			Physician Patholo...	Path review
LP15-0001	Infection Con...	Pap test			Physician Patholo...	Path review
✓ S23-0001	Beaker, Kasey	Tissue Exam			Physician Patholo...	Gross done
F23-0001	Beaker, Kasey	Flow cytometry			Physician Patholo...	Accessioned

Generated Synoptic Results

AI Generated Synoptic Results from Final Diagnosis and findings within the patient's chart:

- Excision
- Residual Invasive Ductal Carcinoma
- Right Breast Mastectomy
- Upper outer quadrant

Extracted Result

Specimen Laterality: Right

Derived from "Right Breast Mastectomy"

TUMOR

Tumor Site (Note B)

- ✓ Upper outer quadrant
- Lower outer quadrant
- Upper inner quadrant
- Lower inner quadrant



CONCEPT